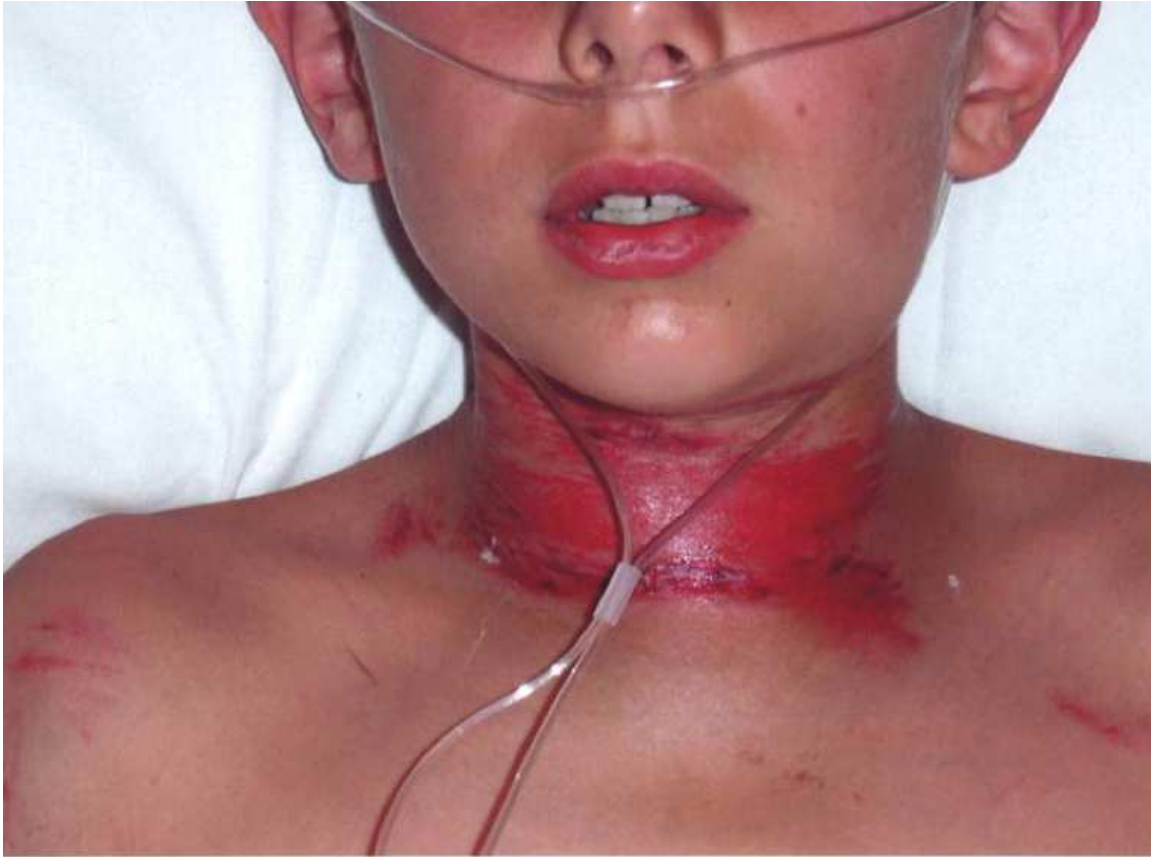


VAQ 2008.2.5 Paed

An 8 year old boy is brought by his parents to your emergency department 20 minutes after a motor vehicle accident in which he was a restrained rear seat passenger.



Describe and interpret his photograph. (100%)

Clinical photograph showing a young boy with a wide area of bruising/abrasion to his entire anterior neck.

This child has sustained a friction burn/abrasion to the anterior neck, likely from a rear driver's side seatbelt without a booster seat. This injury is concerning for deeper neck injury, particularly respiratory and vascular structures but also digestive, bony, neural, and muscular injury.

Photograph

anterior view of child
from midface to upper chest
centred on anterior neck

Patient

oxygen by nasal prongs
distress not assessable
pink, looks well perfused

Injuries

abrasion

functional partial thickness friction burn
almost entirety of anterior neck
directed from patient's upper right to lower left
consistent with rear driver's side seatbelt (or something sensible, though can't think of anything else)
extends into supraclavicular fossa on right

separate minor abrasions also seen
anterior right shoulder
left left sternal
left lateral chest

Interpretation

Seatbelt injury most likely

concerning for deeper structure injury

immediate risk

respiratory structures

tracheal contusion/laceration

laryngeal contusion/laceration/fracture

vascular structures

carotid arteries

dissection, contusion, laceration

internal and external jugular veins

laceration, contusion

other structures

neural

spinal cord (SCIWORA)

brachial plexus injury

recurrent laryngeal nerve injury

digestive

oesophageal

contusion, transection, laceration

skeletal

cervical spine fracture/dislocation

ligamentous injury

endocrine

thyroid/parathyroid contusion/laceration

muscular

platysmal injury

deep neck muscle injury (multiple)

Chest injury

pulmonary

pneumothorax

haemothorax

contusion

rib fracture

sternal fracture

cardiac contusion

great vessel injury